

## Fetal and neonatal ventricular arrhythmias in Long QT type 2 syndrome: a case report

Julie Vanclaire <sup>a</sup>, Christophe Vô <sup>b</sup>

<sup>a</sup>Pediatric Department, Cliniques universitaires Saint-Luc, Brussels, Belgium.

<sup>b</sup>Division of Pediatric cardiology, Pediatric Department, Cliniques universitaires Saint-Luc, Brus-sels, Belgium.

christophe.vo@uclouvain.be

### Keywords

Long QT Syndrome, fetal, arrhythmias, gene mutation, case report

### Abstract

Congenital Long QT syndrome is a family of conditions that share ion channel disturbances that can lead to severe ventricular arrhythmias. This report describes a rare case of fetal presentation, as well as its subsequent perinatal management. The postnatal electrocardiogram revealed ex-treme prolongation of QT interval, ventricular arrhythmias, and atrioventricular block. Patient was treated postnatally using propranolol and mexiletine, with pacemaker implantation. Type 2 LQTS was genetically confirmed. At last follow-up the patient remains free of ventricular arrhythmia. Fetal ventricular arrhythmias must raise suspicion of LQTS. This article provides additionally some practi-cal consideration in regard to diagnosis and treatment of fetal arrhythmia.

### Introduction

Congenital Long QT syndrome (LQTS) is characterized by a prolonged corrected QT (QTc) interval on electrocardiogram (ECG) that possibly leads to arrhythmia-related syncope and sudden death. Thus far, 17 gene mutations involving ion channel have been identified.

Its incidence, estimated at no less than 1 in 2500 births, is probably underestimated, given that some mutations possibly lead to non-penetrance, or result only in subtle clinical abnormalities (1-3).

Patients can experience abrupt symptoms of syncope, cardiac arrest, or even sudden death. The syndrome onset is reported to occur within the first three decades of life for most patients. Never-theless, in some cases, LQTS can be suspected antenatally. We here report a rare case of fetal and postnatal LQTS presentation with severe ventricular arrhythmias and attempt to guide clini-cians in the management of perinatal presentation through our mistakes.

### Case Presentation

A 29 year old Caucasian woman, G1P0, was referred to our tertiary center for fetal cardiologic evaluation at 34 weeks of gestation for frequent premature ventricular contractions (PVC) on routine fetal echography. Previous antenatal evaluations were normal. None of the parents displayed any relevant familial or personal medical history.

Fetal echocardiography demonstrated mild right ventricular dysfunction, moderate tricuspid regurgitation, and ventricular arrhythmias consisting of PVCs and short but frequent ventricular tachycardia (VT) bursts. Owing to the lack of familial history of LQTS, fetal atrio-ventricular block (AVB), and fetal bradycardia, a transplacental therapy with sotalol at 80mg three times per day was initiated under close fetal monitoring, enabling a decrease in cardiac arrhythmias and normalization of right ventricular function. A male baby of 3.41Kg was delivered by cesarean section for monitoring purposes at 38 weeks and 2 days. He was promptly admitted to the pediatric intensive care unit for surveillance. Two hours after birth, he displayed several bursts of VT with compromised hemodynamic parameters. A unique dose of amiodarone was administrated, in an attempt to decrease ventricular arrhythmias. The ECG that was performed in sinus rhythm revealed a significant QTc prolongation (680msec) and 2:1 functional AVB (Figure 1). As cardiac ultrasound demonstrated systolic dysfunction, the patient was intubated for 36 hours. A treatment with continuous intravenous lidocaine

at 15 mcg/Kg/min was initiated, which decreased the burden of VT. At that moment, it was assumed that the QT interval was prolonged due to antenatal treatment with sotalol and postnatal administration of amiodarone. At 24 hours of life, a temporary epicardial pacemaker was inserted in order to ensure a good atrioventricular conduction. At Day 3, following amiodarone discontinuation, the ECG revealed persistent QTc prolongation despite normal electrolytes (Figure 2) and the diagnosis of LQTS was evoked; therefore, lidocaine infusion was ceased and oral propranolol and oral mexiletine were initiated. Due to persistent AV conduction troubles, a permanent epicardial double chamber pacemaker was implanted at Day 22. Six days later, the infant was discharged on propranolol 8mg/Kg/day and mexiletine 4mg/Kg/day, without any ventricular arrhythmia. The case's timeline is summarized in table 1.

Table 1: timeline

	Premature ventricular contractions on routine fetal echography.  Mild right ventricular dilatation, mild left ventricular dysfunction, moderate tricuspid regurgitation, PVCs and VT bursts. Sotalol initiation.
38 weeks 2/7 GA	Cesarean section. Male newborn 3,41kg
H+2	Ventricular tachycardia bursts. Amiodarone ECG : QTc 680ms and 2:1 AVB  Echocardiography : left ventricular dysfunction  Intubation  Persistence of severe ventricular arrhythmias : Lidocaine infusion
H+24	Temporary epicardial pacemaker implantation.
D3	ECG : QTc 620ms  Propranolol and Mexiletin started
D22	Permanent pacemaker implantation
D28	Discharged with Propranolol and Mexiletin

Genetic testing identified a heterozygous mutation in exon 7 of *KCNH2* gene (c.1897A>G, p.(Asn633Asp)), classified as likely pathogenic. Segregation study targeted at *KCNH2* confirmed the “de novo” mutation. Given the clinical presentation and the mutation finding, diagnosis of Type 2 LQTS was retained.

The child remained free of ventricular arrhythmias on unchanged treatment administered for 19 months.

## Discussion

LQTS can lead to life-threatening arrhythmias in form of VT, torsades de pointe (TdP), or ventricular fibrillation (VF), and this condition is a well-known cause of sudden cardiac death. LQTS has been strongly associated with sudden infant death syndrome (SIDS) and is hypothesized to be at the origin of sudden intrauterine death (4).

LQTS can be antenatally suspected when fetal ventricular arrhythmias are observed in the context of a LQTS familial history. When the familial history is unremarkable, the LQTS diagnosis is more challenging, as it requires recognition of specific fetal rhythm abnormalities.

In most centers fetal echocardiography remains the main diagnostic tool for assessing fetal arrhythmias. While it cannot measure the QT interval, several publications have suggested other means for establishing antenatal LQTS diagnosis, mostly based on doppler flux (5-7).

Typical manifestation of in utero LQTS are ventricular arrhythmias and 2:1 AVB, whereas these disturbances account for only 25% of fetuses with postnatally proven LQTS (1, 8, 9). Sinus bradycardia has also been described among the more common (76%) manifestations of LQTS. Nevertheless, fetal bradycardia is less specific, given that LQTS is diagnosed in only 15-17% of all fetal bradycardias <110bpm (2, 9). There seems to be a correlation between rhythm phenotype and genotype. *KCNQ1* gene mutation carriers (Type 1 LQTS) are more prone to develop sinus bradycardia, while *SCN5A* gene mutation carriers (Type 3 LQTS) are more susceptible to develop a more severe phenotype with ventricular arrhythmias and/or 2:1 AVB, whereas *KCNH2* gene mutation carriers (Type 2 LQTS) can develop both phenotypes (10).

As the association between AVB and ventricular arrhythmias should be suggestive of LQTS diagnosis, differential diagnoses of « real » high-degree AVB (as opposed to functional 2:1 AVB) and ventricular arrhythmias must be kept in mind. High-degree AVB can be caused by congenital heart disease, presence of maternal SSA or SSB autoantibodies (isoimmune AVB), or LQTS. As fetal ventricular tachycardia is extremely rare, this condition should evoke the suspicion of in utero cardiomyopathy, myocarditis, ventricular tumor, or LQTS.

Early recognition of this syndrome is imperative for several reasons: it permits to avoid the administration of some QT-prolonging maternal medications; right transplacental therapy can be promptly initiated; close monitoring of fetal distress signs can be scheduled, and postnatal care can be properly anticipated; and there is a higher risk of pre- or postnatal death if not recognized.

Currently, no guidelines for in utero management exist. In many cases, the LQTS fetus with a bradycardia or 2:1 AVB just needs to be observed (11). Intervention is indicated for hydrops fetalis or cardiac dysfunction attributable to ventricular arrhythmias or severe bradycardia. Fetal treatment should be considered if non-sustained ventricular tachycardia occurs, yet without any fetal distress signs.

If management is needed, immediate delivery or initiation of transplacental therapy must be discussed. As prematurity can cause additional morbidity, preterm delivery must be avoided as far as possible. Moreover, pacemaker insertion is often needed in the LQTS newborn and is more easily performed with a higher weight. Those considerations must outbalance the risks and the side-effects of giving pro-arrhythmogenic drugs in a healthy pregnant woman.

Severe ventricular arrhythmias, whether sustained VT and TdP, are most likely to be successfully treated using magnesium sulfate and lidocaine as it has been suggested in few reports.

Magnesium sulfate has been shown to successfully restore sinus rhythm pertaining to severe ventricular arrhythmias, including high burden of VT, VF or TdP (12).

Intravenous lidocaine has also been proposed as transplacental therapy for severe ventricular arrhythmias (13). Nevertheless, lidocaine has been shown to increase in utero ventricular arrhythmias, probably due to sodium channel modifications in *SCN5A* mutation cases (14).

Chronic treatment is often based on beta-blockers, yet other treatments have similarly been investigated.

Beta-blockers are likely the keystone of suspected fetal LQTS. Propranolol is the most frequently used beta-blocker because of its favorable transplacental transfer characteristics. While beta-blockers decrease the fetal VT burden, they appear to be less effective in TdP or VF cases. In addition, beta-blockers decrease fetal heart rate, enabling a 1:1 conduction if a 2:1 AVB is present.

Mexiletine, a class Ib antiarrhythmic drug, has also been tried in some cases, exhibiting variable effects on fetal ventricular arrhythmias (15, 16).

Flecainide has been the topic of several publications, yet it appears unable to decrease ventricular arrhythmias (12).

Sotalol and amiodarone may successfully treat some types of fetal VTs (17); however, in LQTS cases, these drugs often worsen the symptoms, potentially leading to TdP and fetal demise. Retrospectively, sotalol was not a good choice in our case.

Both the efficacy and doses of all those treatments have not yet been investigated in randomized controlled trials; thus, these drugs are all used off-label. Nevertheless, we suggest using beta-blockers in a first attempt to treat in utero ventricular arrhythmias, while avoiding QT interval prolonging drugs like amiodarone or sotalol.

At birth, medication prolonging QT interval should be avoided as well as electrolytic disturbances. First-line treatment includes beta-blocker therapy in all LQTS patients, whether symptomatic or not. Literature shows a preference for propranolol or nadolol, reporting a reduction in both syncope and sudden cardiac death.

In LQTS3 patients, in addition to beta-blocker therapy, mexiletine is recommended, given that it slows Na channel recovery (18). Recent data seem to confirm its efficacy to shorten QT interval in some LQTS2 cases (19). QT prolonging drugs should be avoided in neonatal patient exhibiting ventricular arrhythmias

## Conclusion

By the recognition of some rhythmic patterns, cardiocotogram and fetal echocardiography can help the physician to suspect fetal LQTS. Antenatal sinus bradycardia should raise the possibility of Type 1 LQTS. More severe phenotypes, including 2:1 AVB and ventricular arrhythmias, are often due to Type 2 or Type 3 LQTS. Ventricular arrhythmias need a close follow-up and an aggressive treatment given the high risk of fetal complications (ventricular dysfunction, hydrops fetalis) or sudden intrauterine death. Antenatal therapy of congenital LQTS consists mostly in administering beta-blockers. Severe fetal ventricular arrhythmias seem to be well treated with magnesium sulfate or lidocaine infusion. Those therapies are nevertheless empirical and need further studies to confirm the efficacy of such treatment. With improved knowledge in the genetical field, it is likely that individualized therapy based on genotype could optimize the patient care.

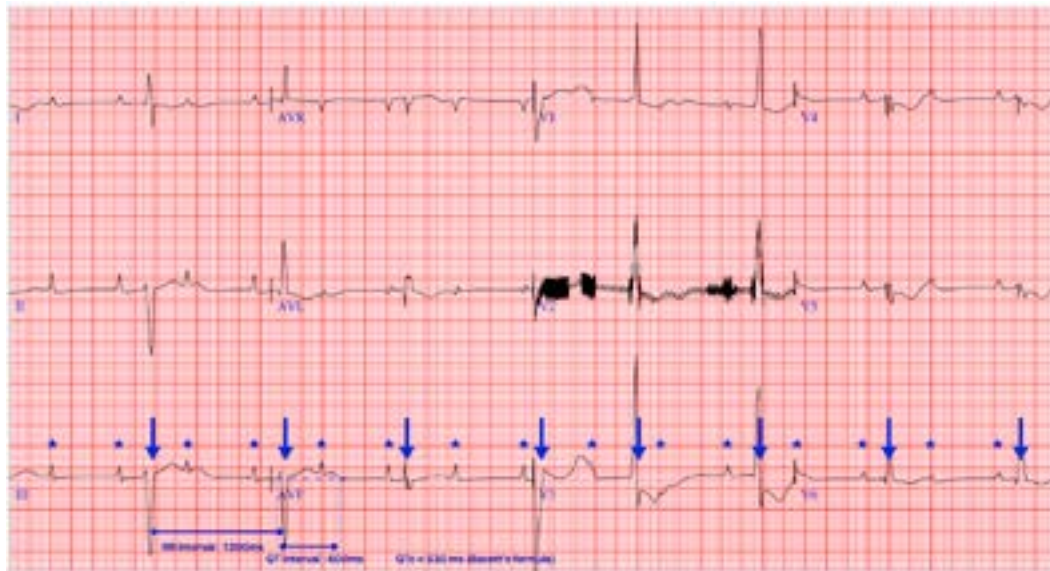## Consent for publication

Written informed consent was obtained from the legal guardians for publication of this case report and any accompanying images.

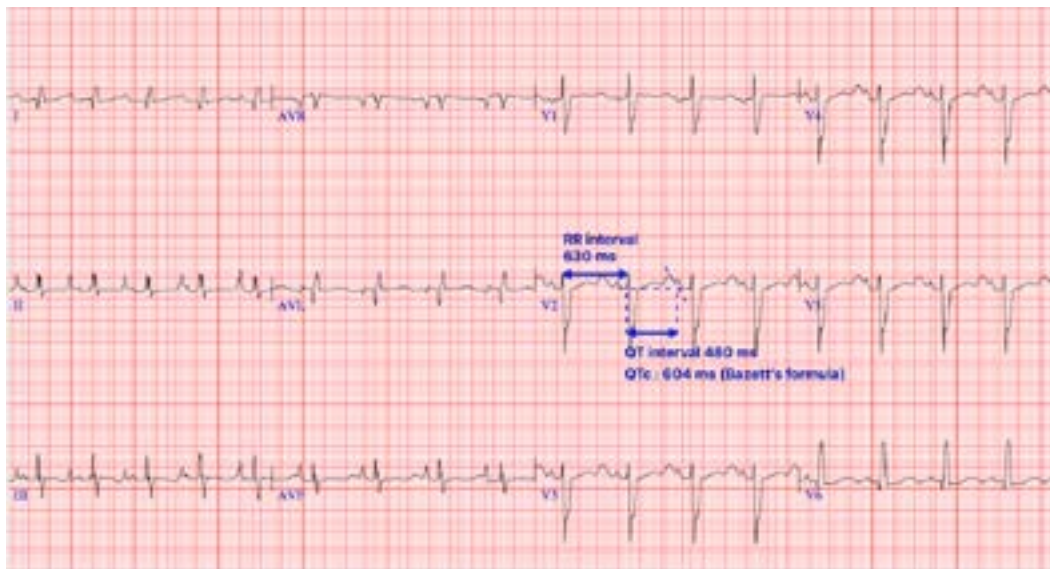
## Competing interests

The authors declare that they have no competing interests.

**Figure 1:** Patient 1: ECG at Day 1 of life showing 2:1 atrioventricular block (Stars : p-wave, Arrows : QRS) due to extreme prolongation of QT interval (600msec)



**Figure 2:** Patient 1: ECG at Day 3 of life after amiodarone discontinuation showing an incomplete left bundle branch block and confirming a prolonged QTc interval evaluated at 604msec



REFERENCES:

1. Ishikawa S, Yamada T, Kuwata T, Morikawa M, Yamada T, Matsubara S, et al. Fetal presentation of long QT syndrome--evaluation of prenatal risk factors: a systematic review. *Fetal diagnosis and therapy*. 2013;33(1):1-7.
2. Mitchell JL, Cuneo BF, Etheridge SP, Horigome H, Weng HY, Benson DW. Fetal heart rate predictors of long QT syndrome. *Circulation*. 2012;126(23):2688-95.
3. Yu S, Ronald Wakai T. In utero Diagnosis of Long QT Syndrome: Challenges, Progress, and the Future. *Journal of pregnancy and child health*. 2015;3(1).
4. Beinder E, Buheitel G, Hofbeck M. Are some cases of sudden intrauterine unexplained death due to the long QT syndrome? *Prenatal diagnosis*. 2003;23(13):1097-8.
5. Chabaneix J, Andelfinger G, Fournier A, Fouron JC, Raboisson MJ. Prenatal diagnosis of long QT syndrome with the superior vena cava-aorta Doppler approach. *American journal of obstetrics and gynecology*. 2012;207(4):e3-7.
6. Miyoshi T, Sakaguchi H, Shiraishi I, Yoshimatsu J, Ikeda T. Potential utility of pulsed-wave Doppler for prenatal diagnosis of fetal ventricular tachycardia secondary to long QT syndrome. *Ultrasound in obstetrics & gynecology : the official journal of the International Society of Ultrasound in Obstetrics and Gynecology*. 2018;51(5):697-9.
7. Takahashi K, Shiraishi H, Ohkuchi A, Matsubara S, Kuwata T, Yada Y, et al. Irregular peak-to-peak intervals between ascending aortic flows during fetal ventricular tachycardia in long QT syndrome. *Ultrasound in obstetrics & gynecology : the official journal of the International Society of Ultrasound in Obstetrics and Gynecology*. 2009;33(1):118-20.
8. Blais BA, Satou G, Sklansky MS, Madnawat H, Moore JP. The diagnosis and management of long QT syndrome based on fetal echocardiography. *HeartRhythm case reports*. 2017;3(9):407-10.
9. Cuneo BF, Strasburger JF, Wakai RT. The natural history of fetal long QT syndrome. *Journal of electrocardiology*. 2016;49(6):807-13.
10. Cuneo BF, Etheridge SP, Horigome H, Sallee D, Moon-Grady A, Weng HY, et al. Arrhythmia phenotype during fetal life suggests long-QT syndrome genotype: risk stratification of perinatal long-QT syndrome. *Circulation Arrhythmia and electrophysiology*. 2013;6(5):946-51.
11. Batra AS, Balaji S. Fetal arrhythmias: Diagnosis and management. *Indian pacing and electrophysiology journal*. 2019;19(3):104-9.
12. Simpson JM, Maxwell D, Rosenthal E, Gill H. Fetal ventricular tachycardia secondary to long QT syndrome treated with maternal intravenous magnesium: case report and review of the literature. *Ultrasound in Obstetrics & Gynecology*. 2009;34(4):475-80.
13. Tanel RE, Rhodes LA. Fetal and neonatal arrhythmias. *Clinics in perinatology*. 2001;28(1):187-207, vii.
14. Lin MT, Wu MH, Chang CC, Chiu SN, Thériault O, Huang H, et al. In utero onset of long QT syndrome with atrioventricular block and spontaneous or lidocaine-induced ventricular tachycardia: compound effects of hERG pore region mutation and SCN5A N-terminus variant. *Heart rhythm*. 2008;5(11):1567-74.
15. Cuneo BF, Ovadia M, Strasburger JF, Zhao H, Petropoulos T, Schneider J, et al. Prenatal diagnosis and in utero treatment of torsades de pointes associated with congenital long QT syndrome. *The American journal of cardiology*. 2003;91(11):1395-8.
16. Miyake A, Sakaguchi H, Miyazaki A, Miyoshi T, Aiba T, Shiraishi I. Successful prenatal management of ventricular tachycardia and second-degree atrioventricular block in fetal long QT syndrome. *HeartRhythm case reports*. 2017;3(1):53-7.
17. Schleich JM, Bernard Du Haut Cilly F, Laurent MC, Almange C. Early prenatal management of a fetal ventricular tachycardia treated in utero by amiodarone with long term follow-up. *Prenatal diagnosis*. 2000;20(6):449-52.
18. Chang IK, Shyu MK, Lee CN, Kau ML, Ko YH, Chow SN, et al. Prenatal diagnosis and treatment of fetal long QT syndrome: a case report. *Prenatal diagnosis*. 2002;22(13):1209-12.
19. Bos JM, Crotti L, Rohatgi RK, Castelletti S, Dagradi F, Schwartz PJ, et al. Mexiletine Shortens the QT Interval in Patients With Potassium Channel-Mediated Type 2 Long QT Syndrome. *Circulation Arrhythmia and electrophysiology*. 2019;12(5):e007280.